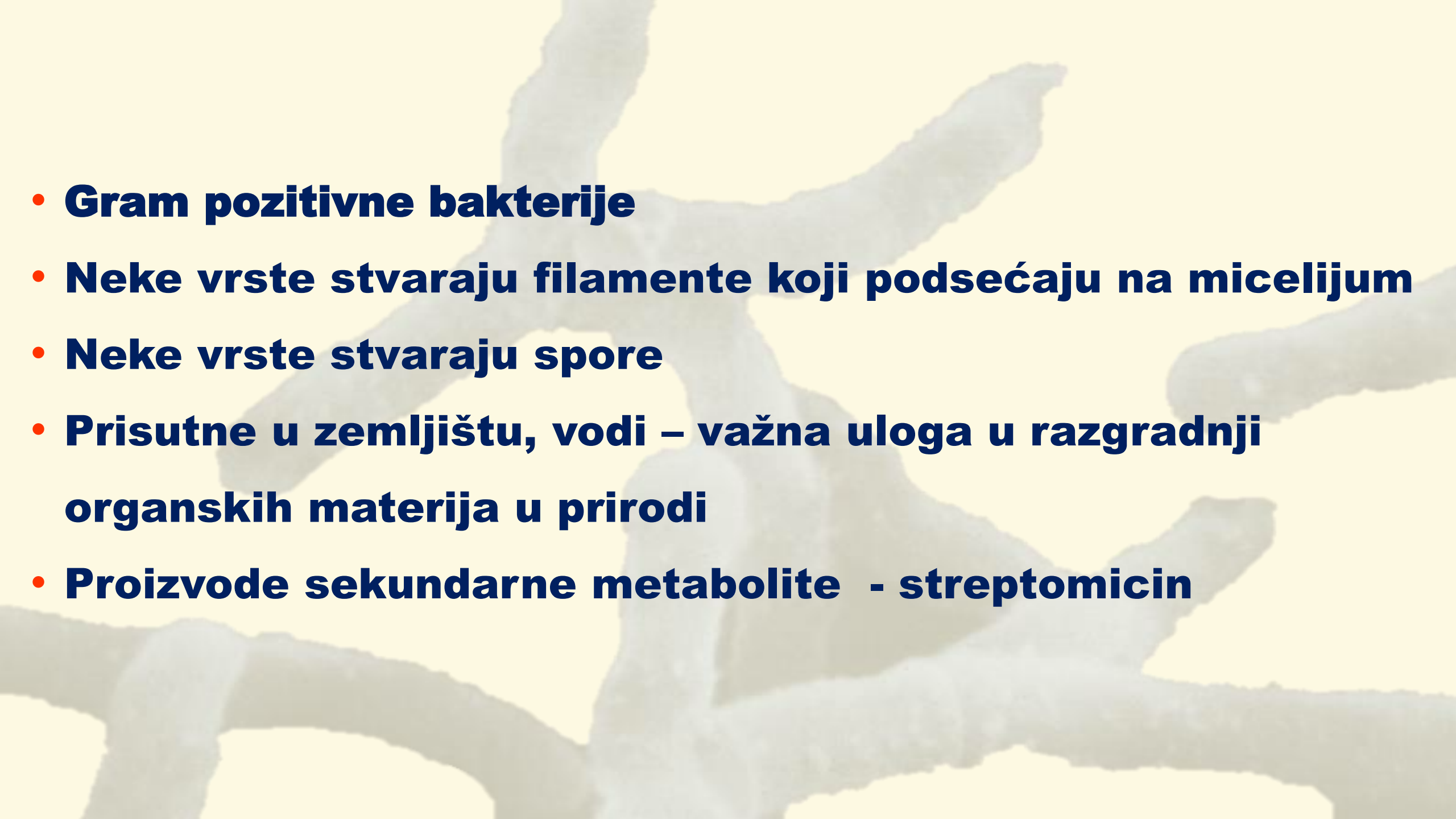


# ***Actinobacteria***

- 
- A background image showing a network of thick, white, branching filaments, likely representing Gram-positive bacterial structures such as actin filaments or spore chains, set against a light yellow background.
- **Gram pozitivne bakterije**
  - **Neke vrste stvaraju filamente koji podsećaju na micelijum**
  - **Neke vrste stvaraju spore**
  - **Prisutne u zemljištu, vodi – važna uloga u razgradnji organskih materija u prirodi**
  - **Proizvode sekundarne metabolite - streptomycin**

**Gram pozitivne bakterije  
sa visokim G+C**

**Stvaraju  
filamente**

**Bez  
micelijuma**

**Bez  
konidiospora**

**Stvaraju  
konidiospore**

**Acidorezistentne  
*Mycobacterium***

**Nisu  
acidorezistentne**

**Acido rezistentne  
*Nocardia***

**Fiksiraju N<sub>2</sub>  
*Frankia***

**Aerobne  
*Streptomyces***

**Anaerobne  
*Actinomyces***

**Gram  
pozitivne**

**Gram varijabilne  
*Gardereella***

***Corynebacterium***

***Propionibacterium***

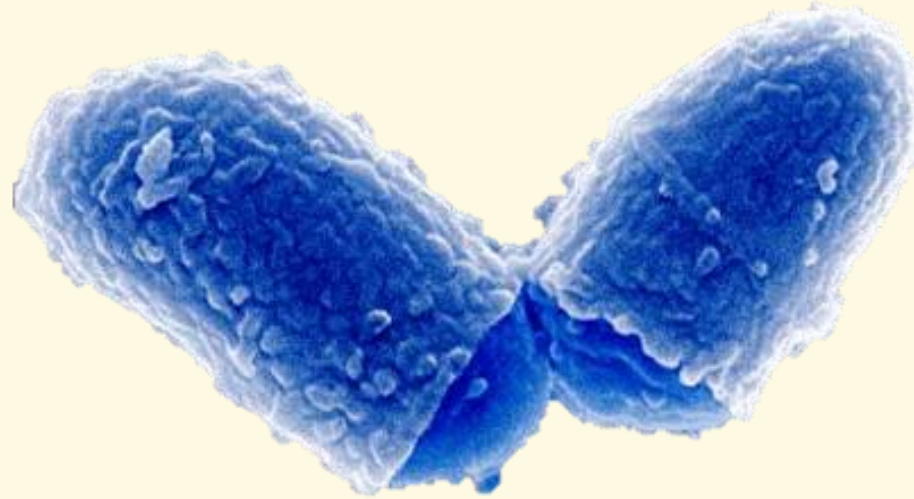
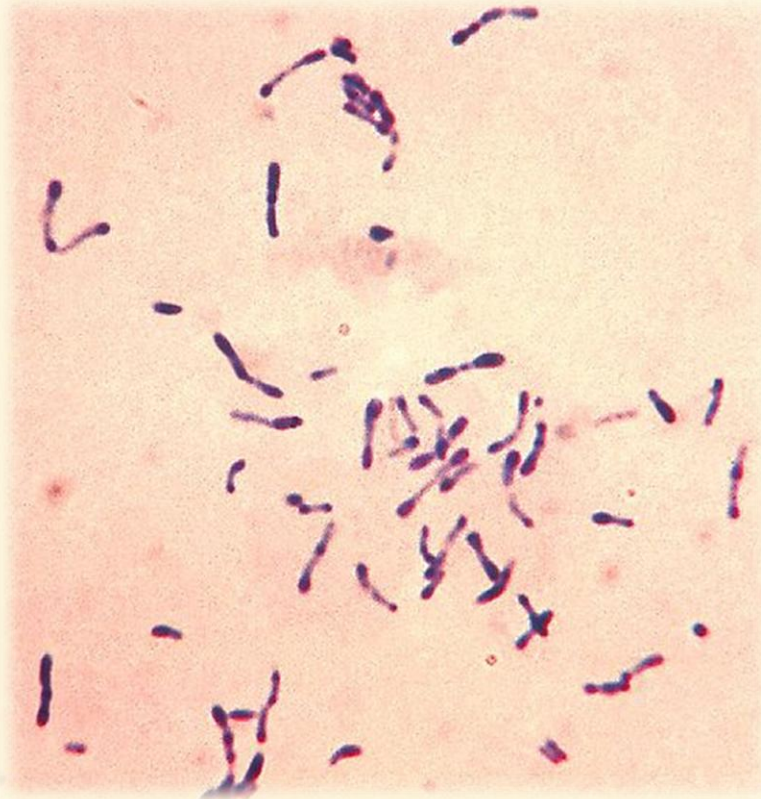


***Corynebacterium***  
**spp.**



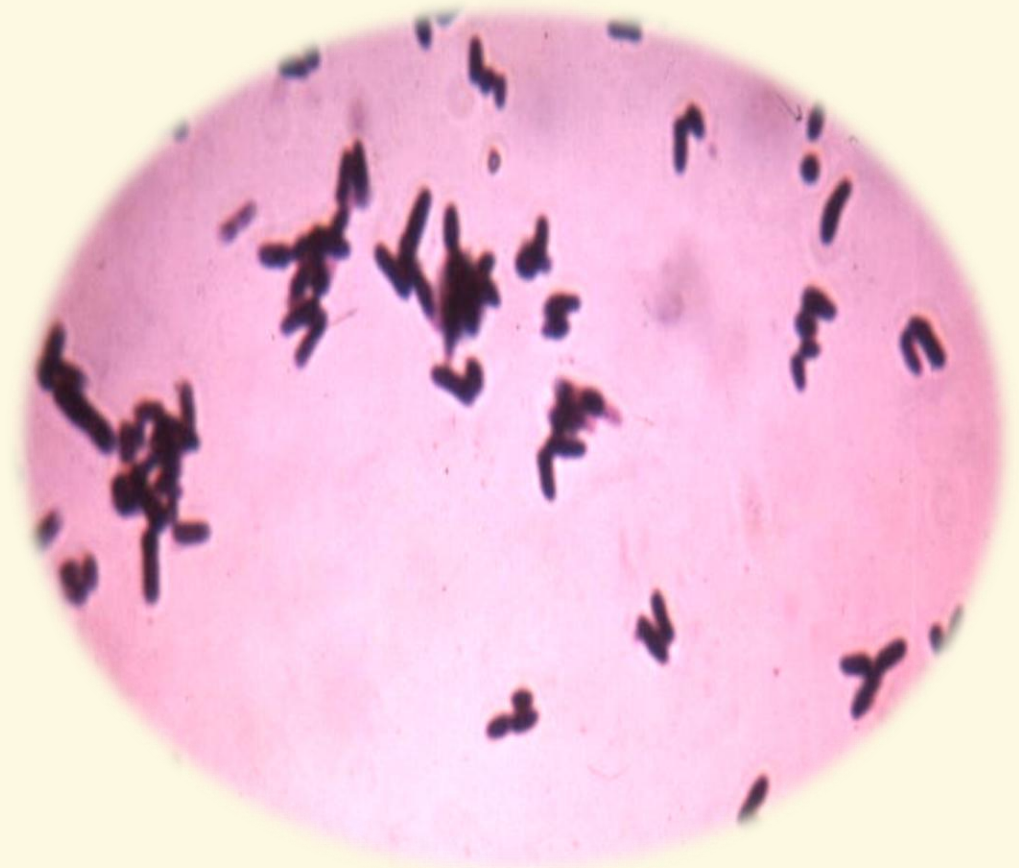
1

# ***Corynebacterium* spp.**



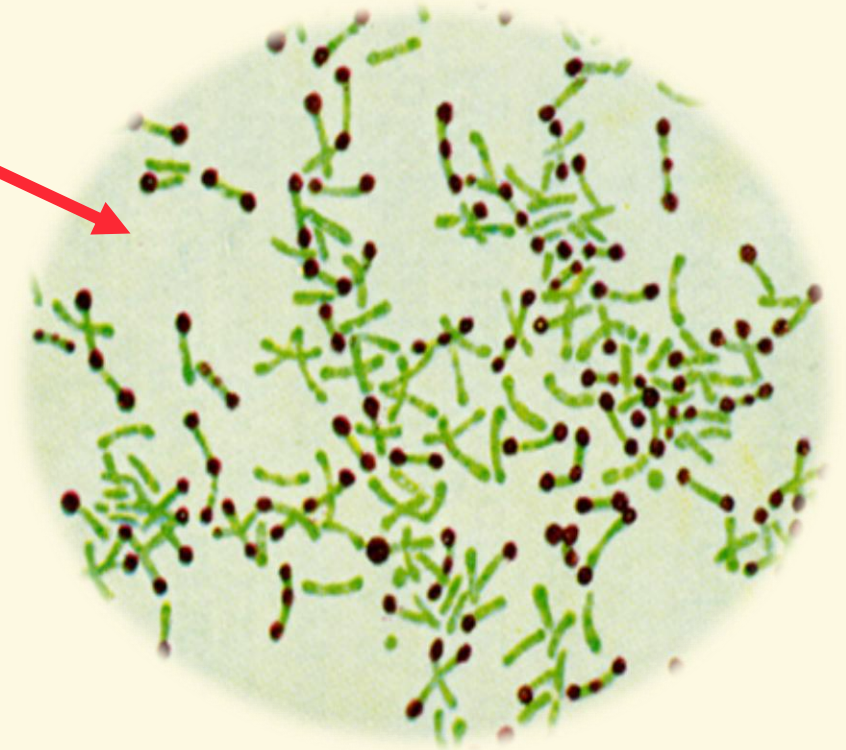

- ***Corynebacterium diphtheriae* je izazivač akutne infektivne bolesti ljudi difterije**
- **Međusobno su preklopljene i izgledaju poput V, Y, L**
- **Paralelno poredane jedna pored druge bakterije izgledaju poput palisada**
- **Oštećenje tkiva obično prethodi infekciji**
- **Komensalni mikroorganizmi na sluznicama i koži**
- **Otporni u spoljašnjoj sredini**

- **Sitne, pleomorfne Gram pozitivne bakterije štapićastog oblika koje mogu biti sferične ili sa zadebljanim krajevima**
- **Katalaza + oksidaza –**
- **Asporogene**
- **Fakultativno anaerobne**
- **Uglavnom nepokretne**



- U ćelijskom zidu imaju mezo-diamino-pimelinsku kiselinu, arabinogalaktan i mikolinsku kiselinu
- ***Corynebacterium spp.*, *Mycobacterium spp.* i *Nocardia spp.***
- Metahromatske granule depo energije


**Fosfati - bojenje po Neisser-u**





# ***Corynebacterium pseudotuberculosis***

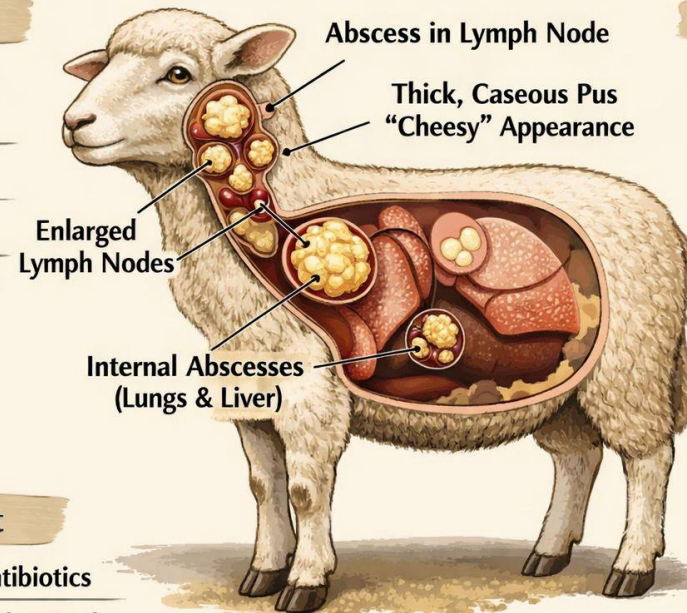
- **Sojevi koji ne redukuju nitrate - ovce i koze pseudotuberkuloza, kazeozni limfadenitis**



## **Caseous Lymphadenitis in Sheep**

### **Symptoms**

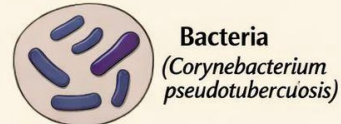
- Swollen Lymph Nodes
- Weight Loss
- Weakness
- Chronic Cough



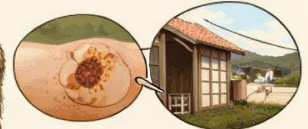### **Treatment**

- Drainage & Antibiotics
- Isolate Infected Animals

### **Transmission**



Bacteria  
(*Corynebacterium pseudotuberculosis*)



Contaminated Wounds



Contaminated Equipment & Environment

### **Prevention**

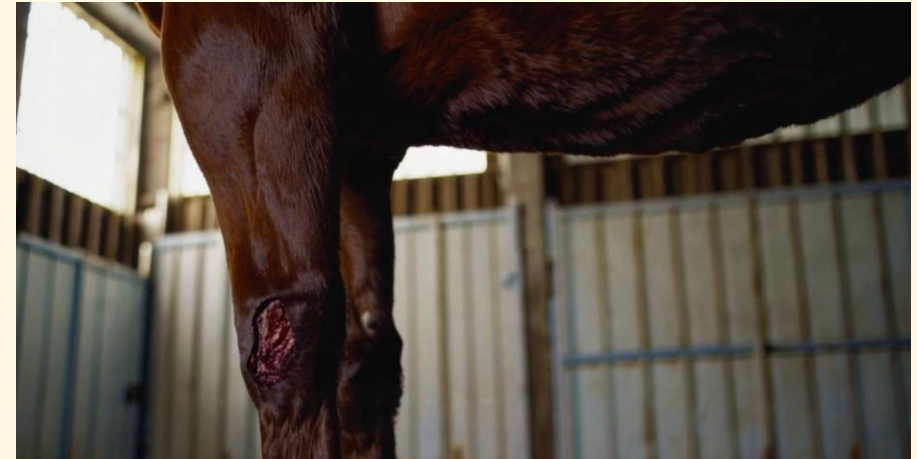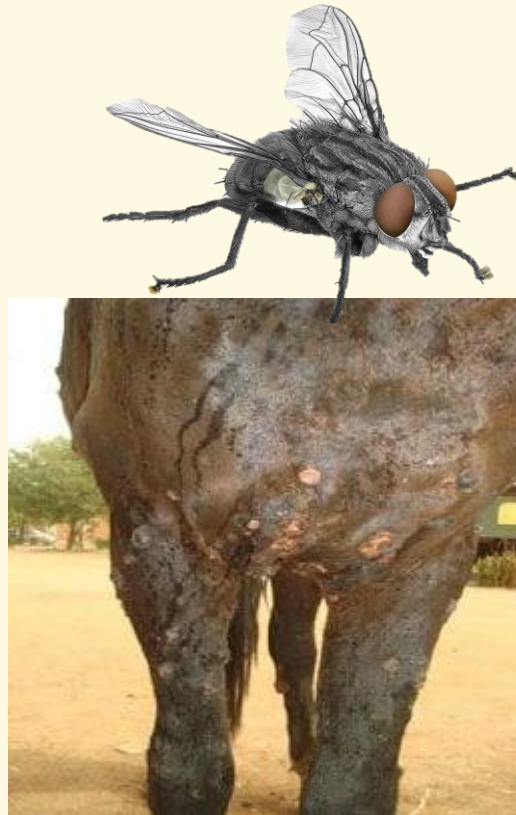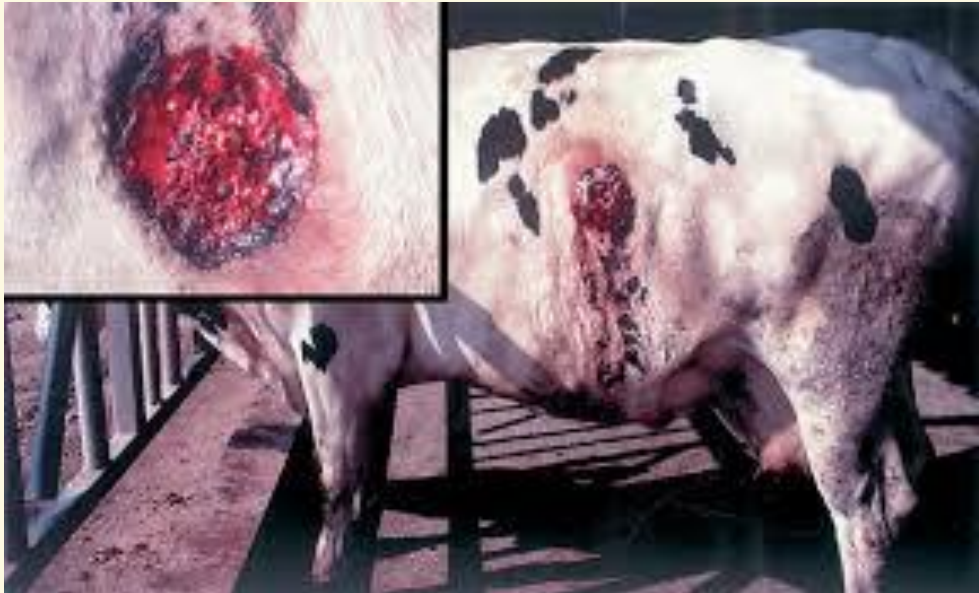- Good Hygiene
- Vaccination
- Quarantine New Animals

*Swagx Vet Clinic*



# *Corynebacterium pseudotuberculosis*

## Ulcerativni limfangitis konja i goveda





## ***C. renale* grupa**

***C. renale* (tip I ) - infekcije urogenitalnog sistema**

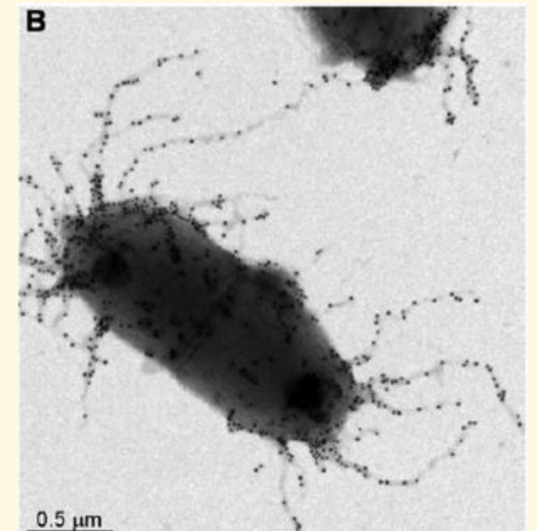
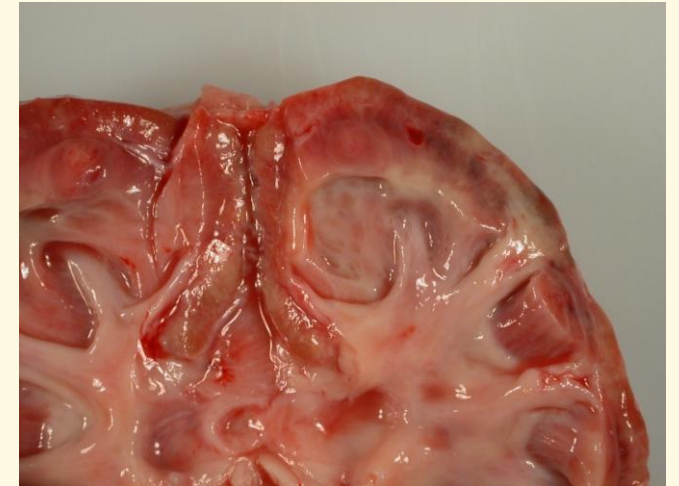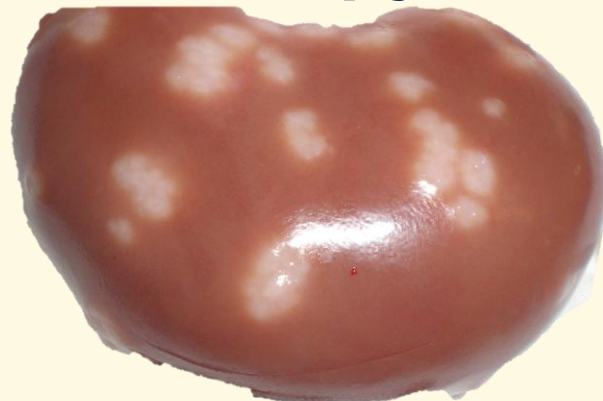**goveda- pijelonefritis i cistitis**

**svinje -apscesi u bubrezima**

**ovnovi i jarci – ulcerativni balanopostitis**

***C. cystitidis* (tip II ) – goveda - cistitis i pijelonefritis**

***C. pilosum* (tip III ) – goveda- cistitis i ređe pijelonefritis**



***C. bovis*** – goveda – supklinički mastitis

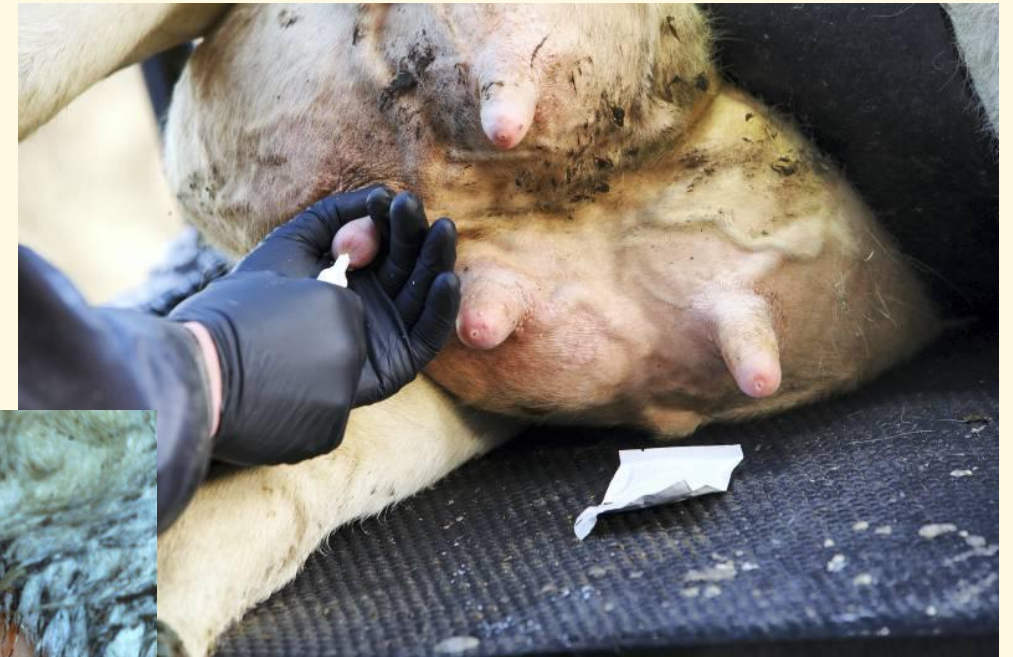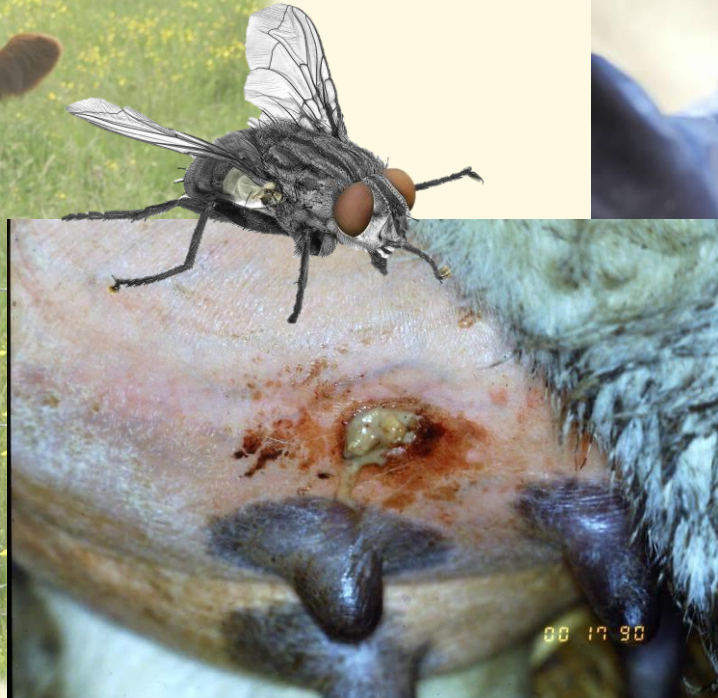***C. ulcerans*** – goveda – mastitis





## ***Trueperella (Arcanobacterium/Actinomyces) pyogenes***

- **Preživari i svinje - gnojne infekcije pluća, endometritis, piometra..**
- **Krave – endometritis, letnji mastitis**
- **Aerob ali i anaerob – idealni uslovi 7% CO2**



<https://www.vetlexicon.com/bovis/udder-health/client-factsheets/summer-mastitis/>  
<https://www.farmersjournal.ie/beef/breeding-and-health/summer-mastitis-symptoms-treatment-and-prevention-213909>

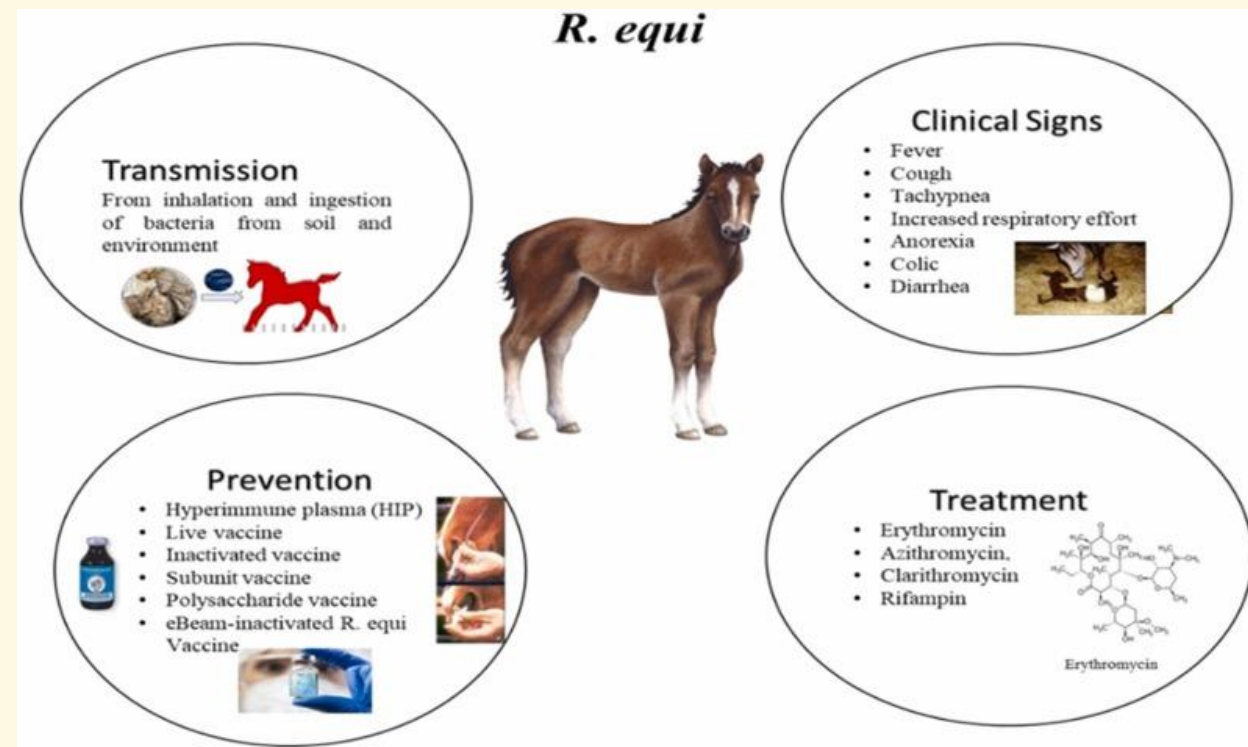


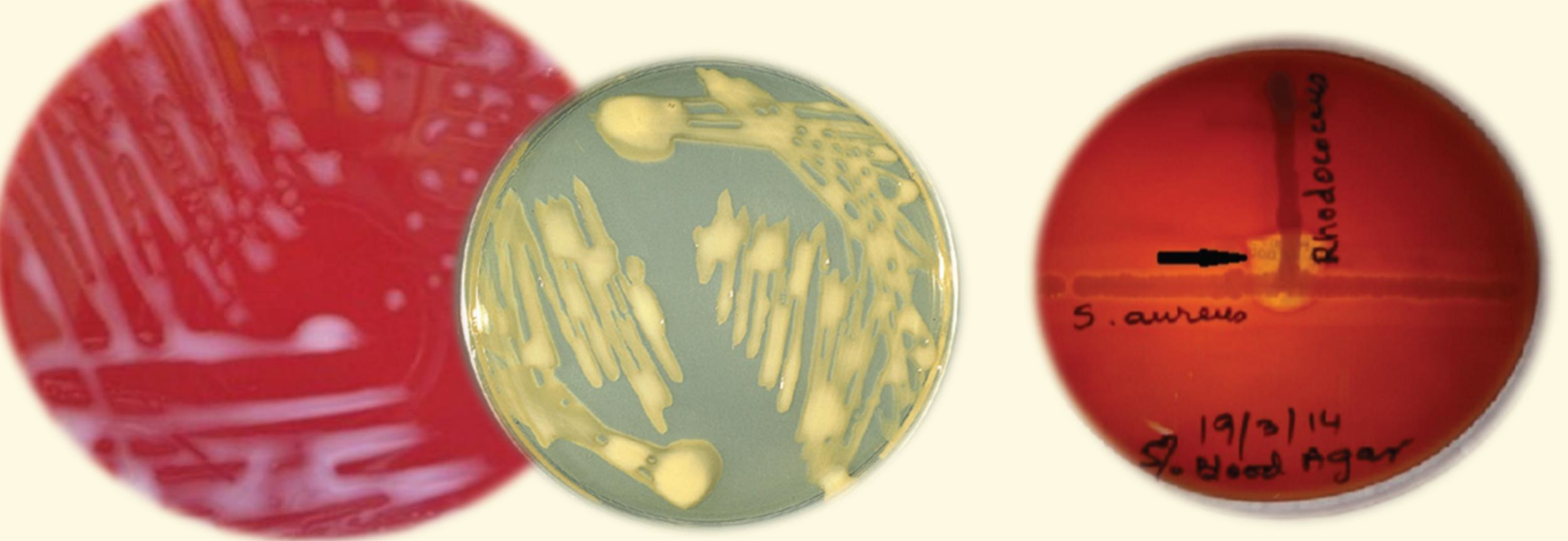
# *Rhodococcus equi*

• **Ždrebac - bronhopneumonija i apscesi u plućima**

• **Konji – apscesi**

• **Mačke – supkutani apscesi, medijastinalni granulomi**





**Raste i na običnim podlogama i stvara karakteristične sluzave, žučkasto-ružičaste kolonije, nema hemolize**

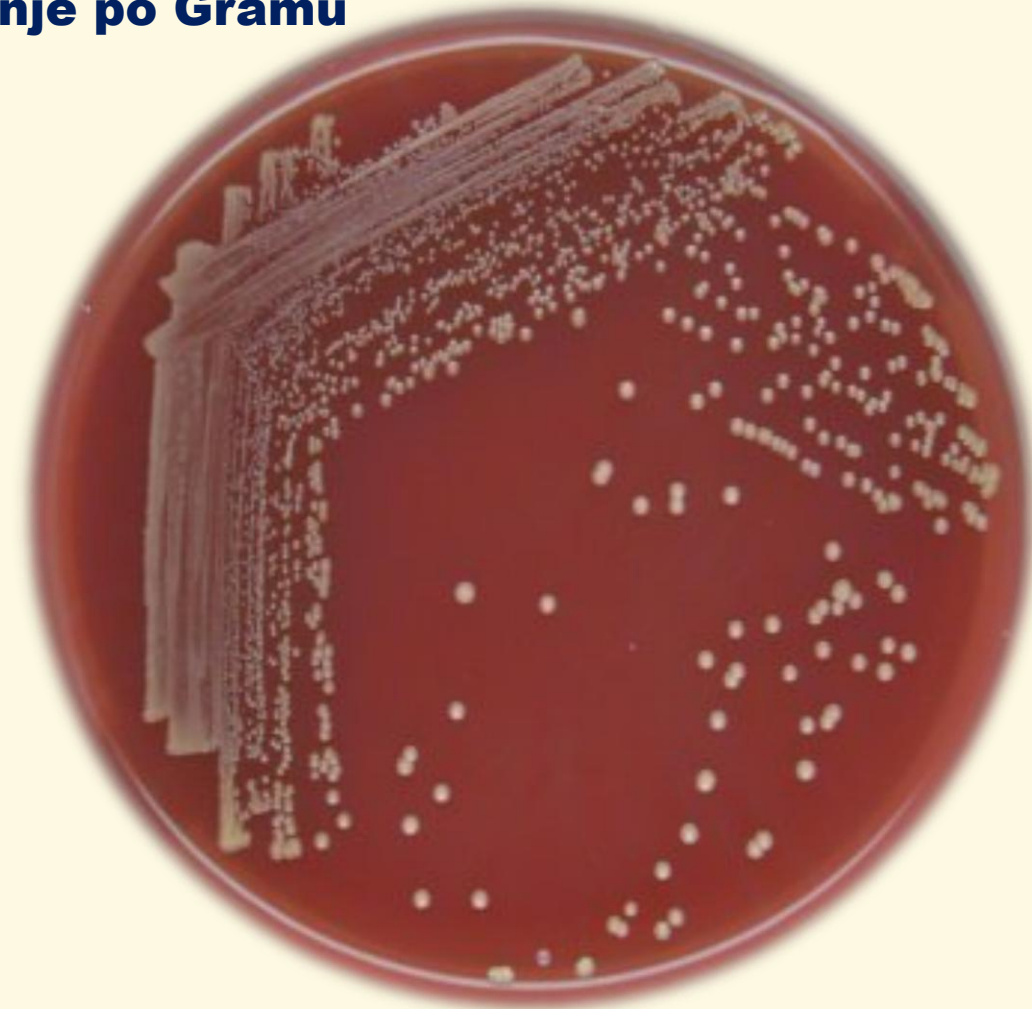
***R. equi* faktori – fosfolipaza C i holesterol oksidaza liza eritrocita uz sinergizam *C. psedotuberculosis***

**CAMP fenomen sa *S. aureus***

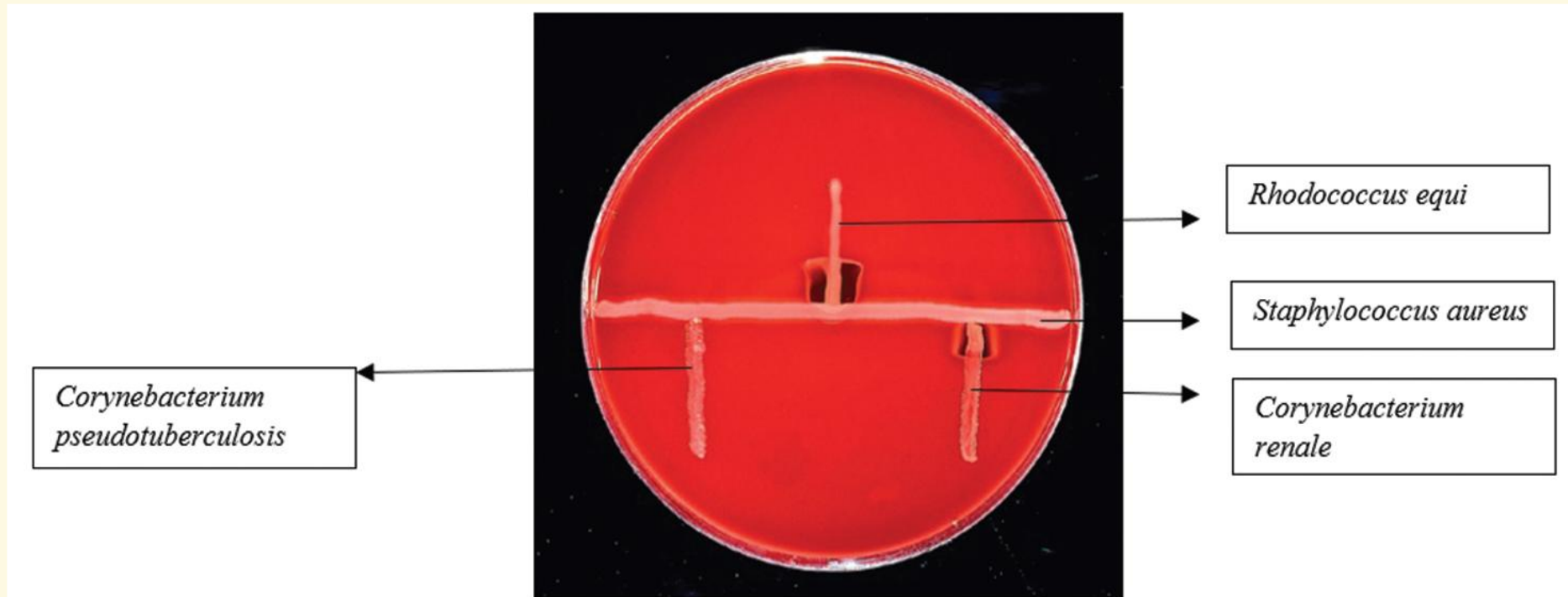


# Laboratorijska dijagnostika

- **Direktan mikroskopski preparat iz materijala - bojenje po Gramu**
- **Izolacija krvni agar, aerobni uslovi, 37°C, 24-48h**
  - **karakteristike kolonija,**
  - **pigment, konzistencije,**
  - **veličina, hemoliza**
  - **biohemijske karakteristike**



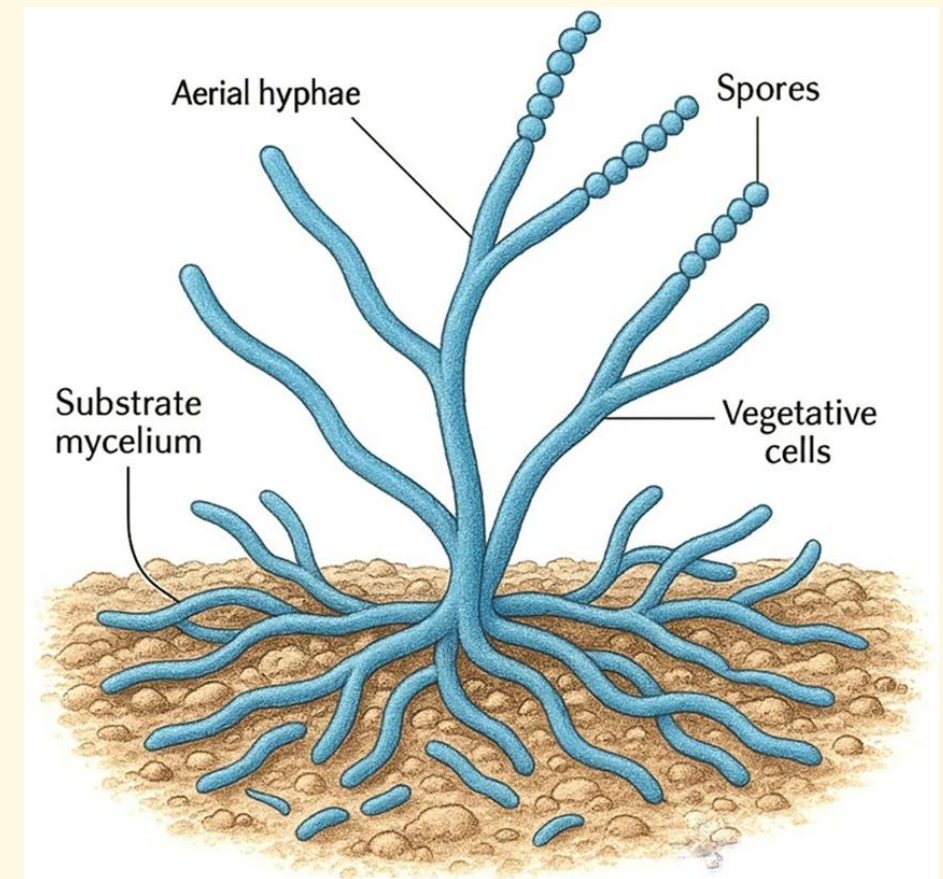
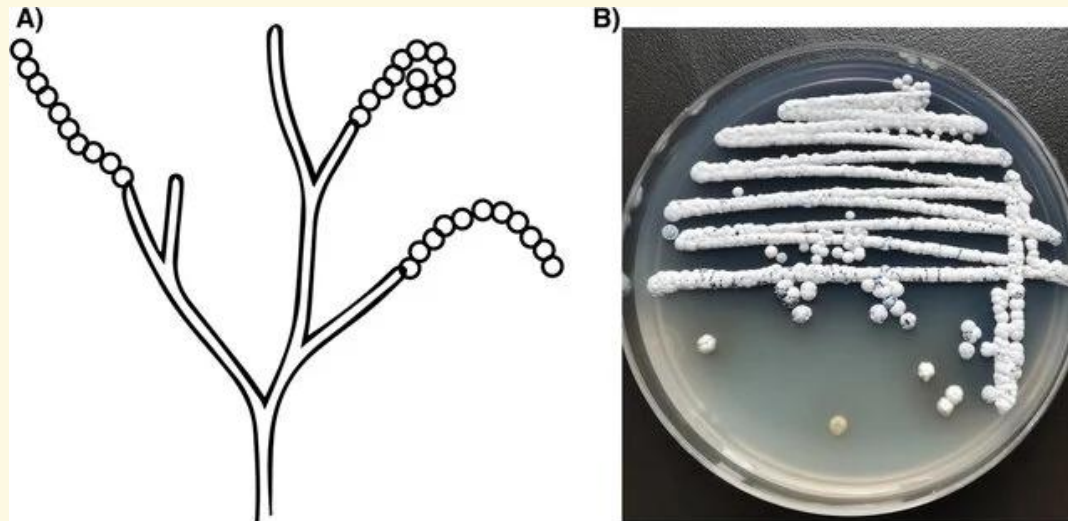
- *C. pseudotuberculosis* inhibiše aktivnost  $\beta$  toksina *S.aureus* a potencirana je hemoliza sa *R.equi* faktorima
- *C. renale* CAMP fenomen sa *S.aureus*





**Filamentozne bakterije**  
***Streptomyces,***  
***Actinomyces* i *Nocardia***  
**vrste**


- **Filamentozne Gram pozitivne bakterije**
- **Stvaraju micelijum poput plesni**
- **Spore *Streptomyces* se nazivaju konidije koje se nalaze u aeralnom delu micelijuma**
- **Zemljište**
- **Striktni aerobi**
- **Otkriveno preko 500 različitih antibiotika**



## From Soil



## To Solution





## Najvažniji antibiotici koje sintetišu *Streptomyces* spp.

**Table 16.10** Some common antibiotics synthesized by species of *Streptomyces*

Chemical class	Common name	Produced by	Active against <sup>a</sup>
Aminoglycosides	Streptomycin	<i>S. griseus</i> <sup>b</sup>	Most gram-negative <i>Bacteria</i>
	Spectinomycin	<i>Streptomyces</i> spp.	<i>M. tuberculosis</i> , penicillinase-producing <i>N. gonorrhoeae</i>
	Neomycin	<i>S. fradiae</i>	Broad spectrum, usually used in topical applications because of toxicity
Tetracyclines	Tetracycline	<i>S. aureofaciens</i>	Broad spectrum, gram-positive and gram-negative <i>Bacteria</i> , rickettsias and chlamydias, <i>Mycoplasma</i>
	Chlortetracycline	<i>S. aureofaciens</i>	As for tetracycline
Macrolides	Erythromycin	<i>Saccharopolyspora erythraea</i>	Most gram-positive <i>Bacteria</i> , frequently used in place of penicillin, <i>Legionella</i>
	Clindamycin	<i>S. lincolnensis</i>	Effective against obligate anaerobes, especially <i>Bacteroides fragilis</i>
Polyenes	Nystatin	<i>S. noursei</i>	Fungi, especially <i>Candida</i> infections
	Amphotericin B	<i>S. nodosus</i>	Fungi
None	Chloramphenicol	<i>S. venezuelae</i>	Broad spectrum; drug of choice for typhoid fever

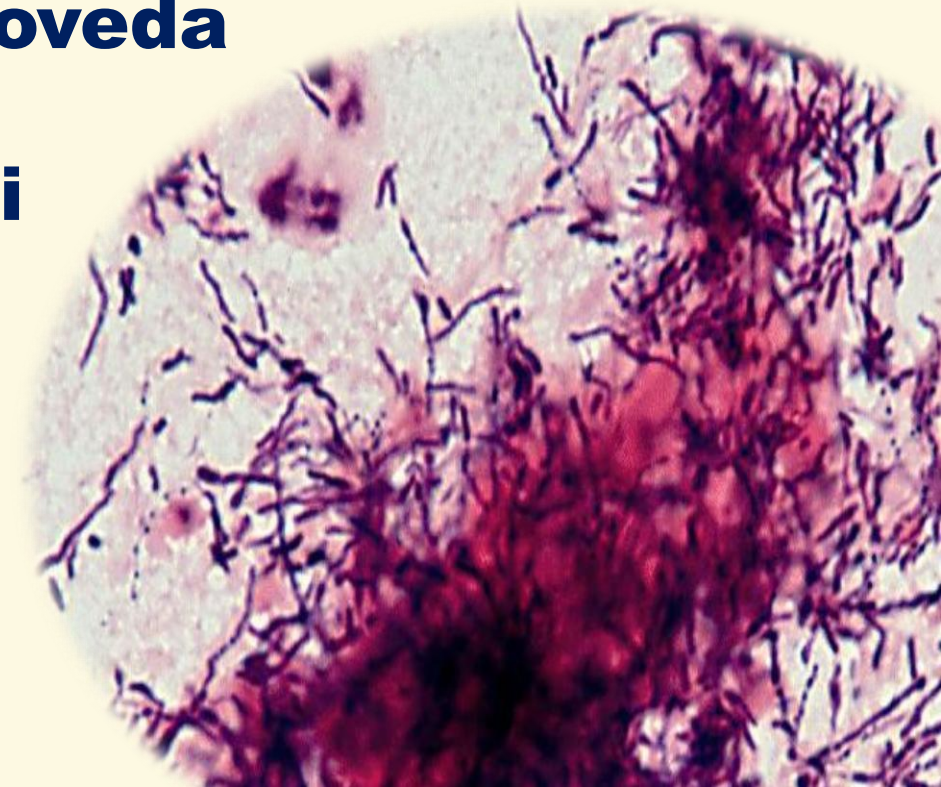

<sup>a</sup>Most antibiotics are effective against several different *Bacteria*. The entries in this column refer to the common clinical application of a given antibiotic. The structures and mode of action of many of these antibiotics are discussed in Sections 27.6–27.9.

<sup>b</sup>All listings beginning with an “S.” are species of the genus *Streptomyces*.



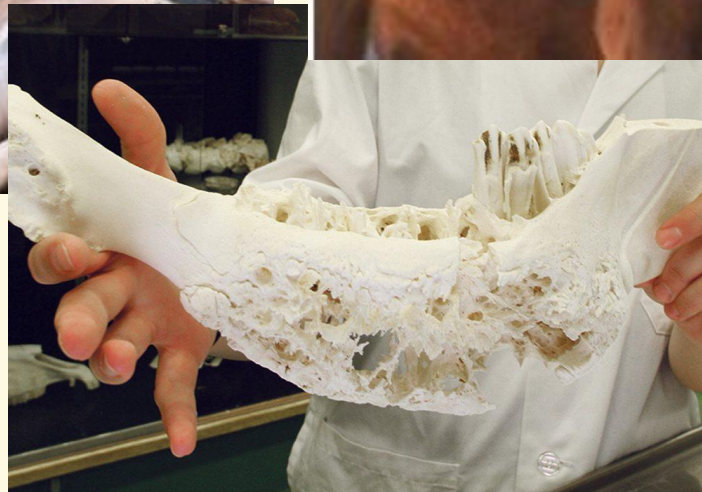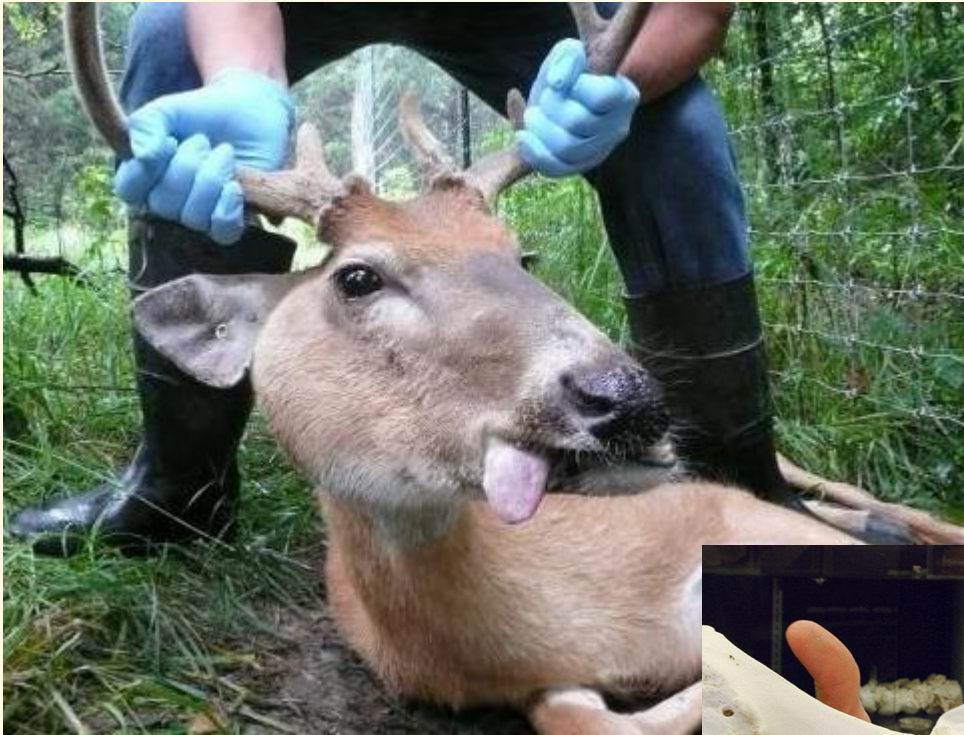## ***Actinomyces* spp.**

- **Dugački lanci ili filamenti**
- **Fakultativni anaerobi**
- ***Actinomyces bovis* - aktinomikoza goveda**
  - **Sumporne granule, rozete**
- ***Actinomyces israeli* – gnojni procesi**
- ***Actinomyces viscosus***



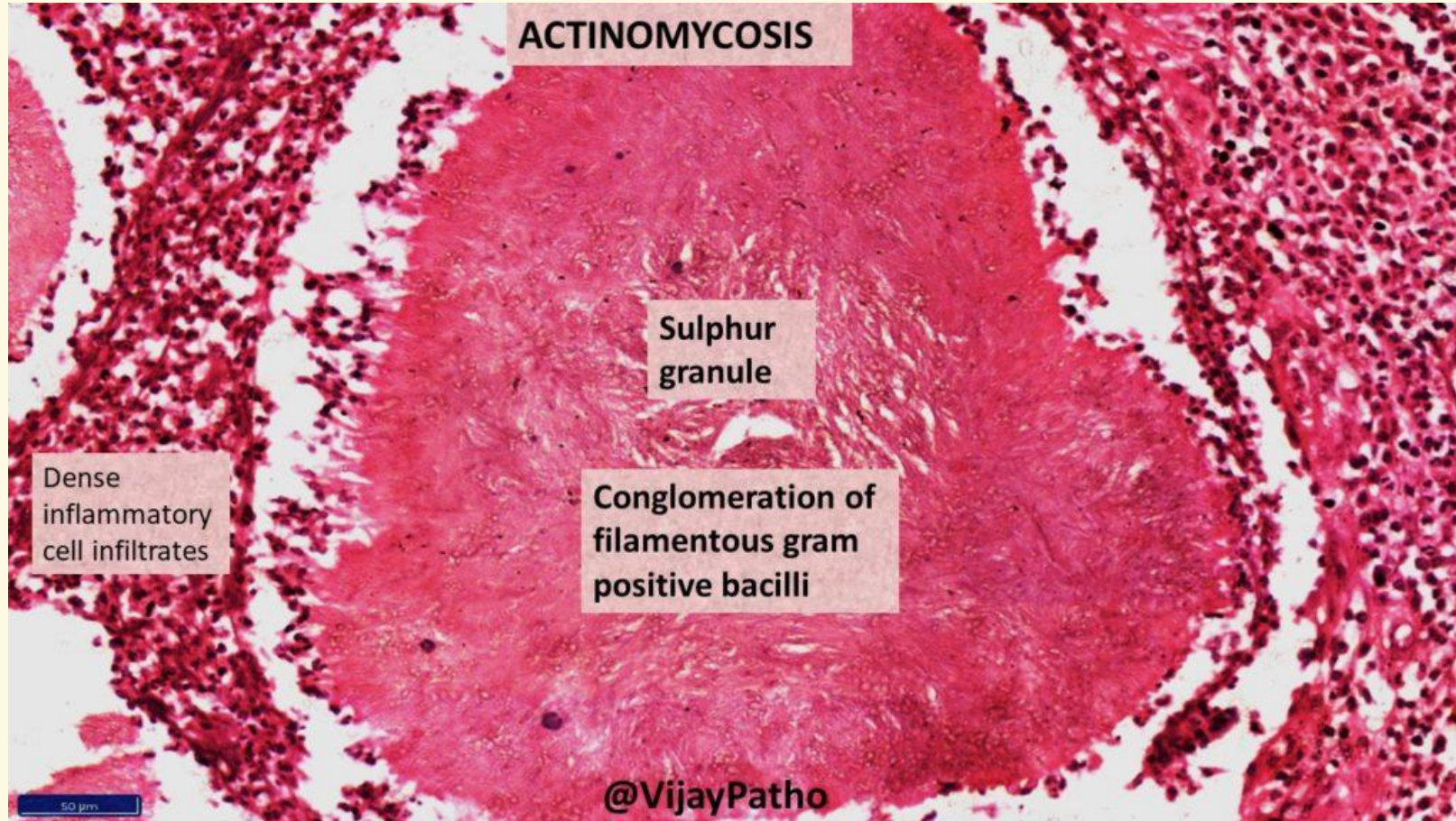


# ***Actinomyces bovis* - aktinomikoza goveda**





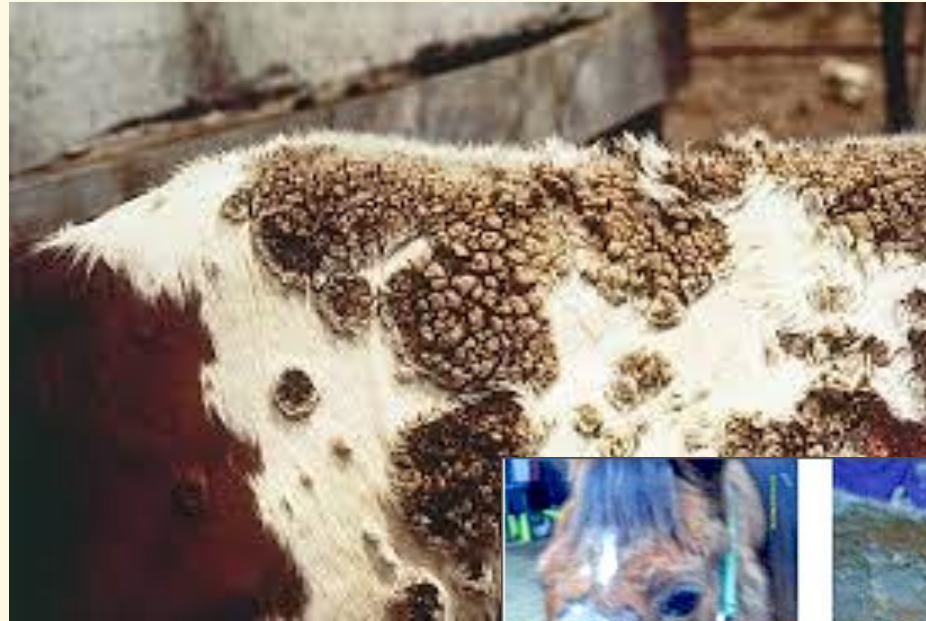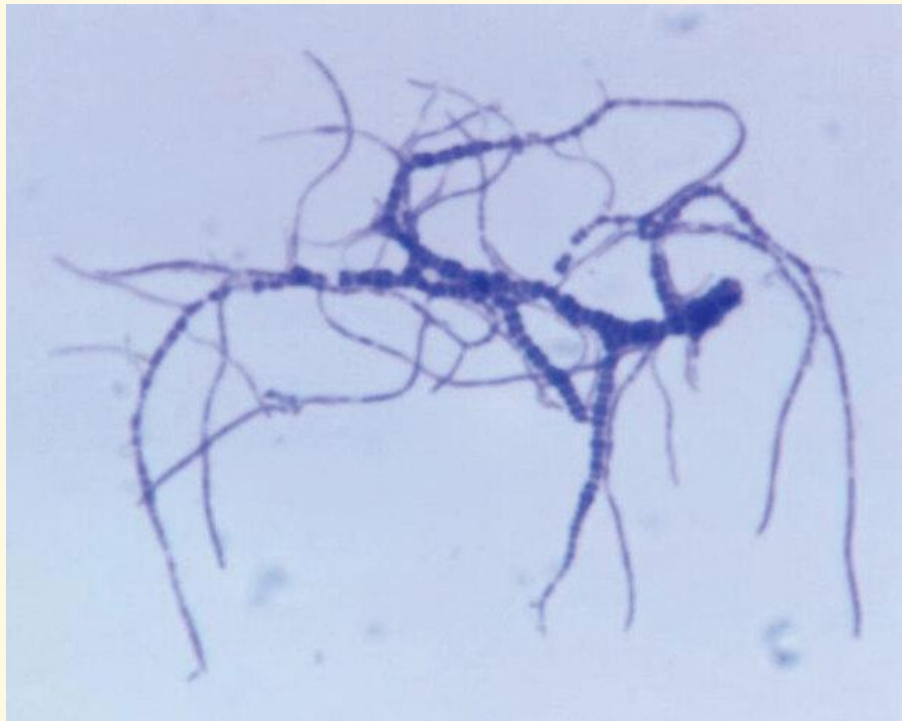# Sumporne granule



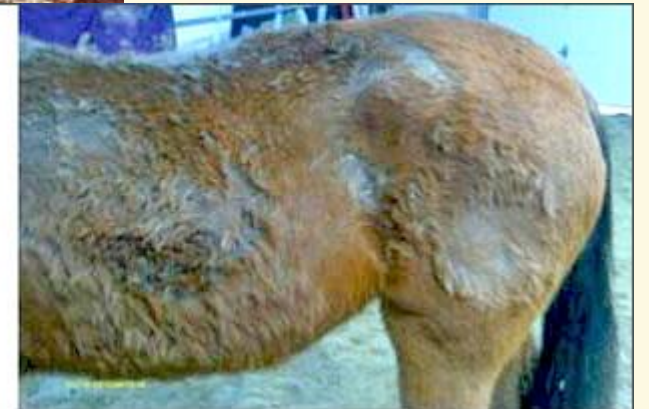

# ***Dermatophilus congolensis***

- ***Dermatophilus congolensis*** – spirotrihoza goveda
- **Stvara zoospore**



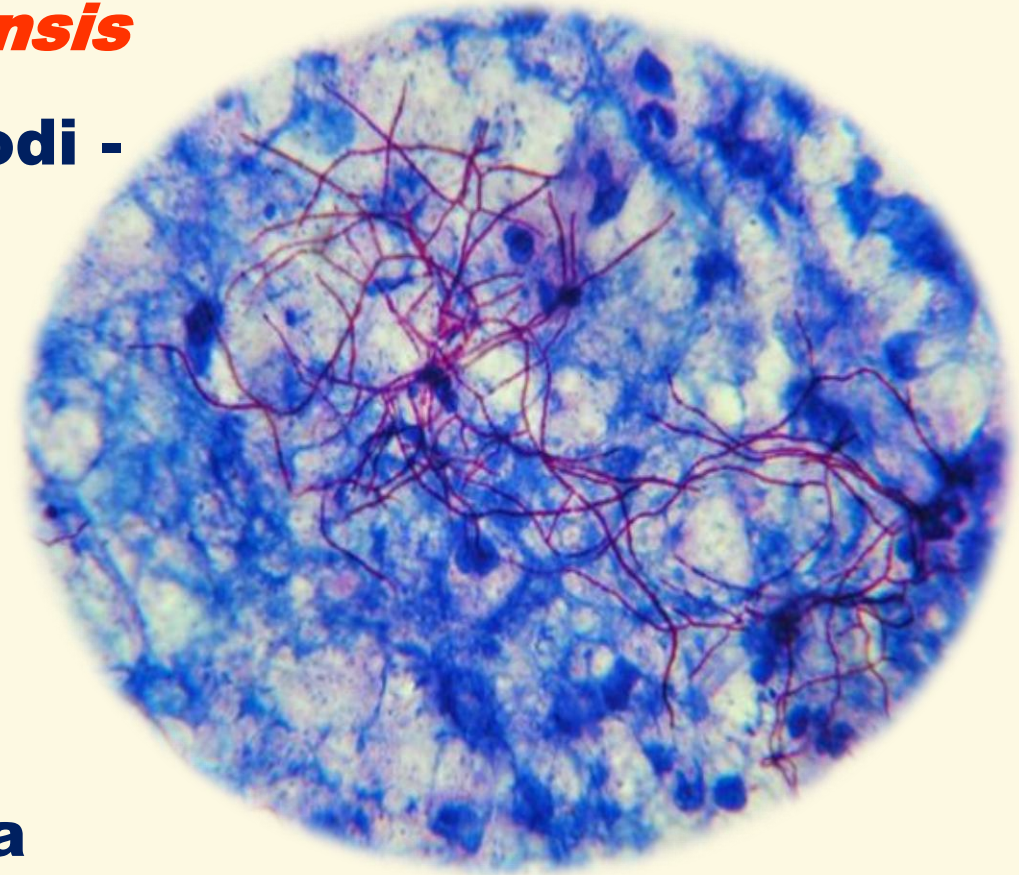
Ambrose N, Lloyd D, Maillard JC. Immune responses to *Dermatophilus congolensis* infections. *Parasitol Today*. 1999;15(7):295-300. doi:10.1016/s0169-4758(99)01470-2





## ***Nocardia spp.***

- ***N. asteroides* , *N. farcinica*, *N. brasiliensis***
- **Saprofiti, široko rasprostranjeni u prirodi - zemljište**
- **Supkutane infekcije, infekcije pluća i apscesi u mozgu**
- **Psi – gnojni granulomi**
- **Goveda – mastitis, abortus**
- **Infekcije rana kod većeg broja životinja**





AKADÉMIAI KIADÓ

Acta Veterinaria  
Hungarica

71 (2023) 2, 65–70

DOI:


[10.1556/004.2023.00893](https://doi.org/10.1556/004.2023.00893)

© 2023 Akadémiai Kiadó, Budapest

SHORT  
COMMUNICATION



# Multilocus sequence analysis (MLSA) of a *Nocardia cyriacigeorgica* strain causing severe bovine mastitis in Bosnia and Herzegovina

OLIVER STEVANOVIĆ<sup>1</sup>, DUBRAVKA MILANOV<sup>2</sup>,  
ISIDORA PROŠIĆ<sup>3</sup>, VLADIMIR GAJDOV<sup>2</sup>, DRAGO NEDIĆ<sup>1</sup>,  
ŽELJKO SLADOJEVIĆ<sup>1</sup> and ANDREA RADALJ<sup>3\*</sup> 

<sup>1</sup> Veterinary Institute of the Republic of Srpska „Dr. Vaso Butozan”, Branka Radičevića 18, Banja Luka 78000, Republic of Srpska, Bosnia and Herzegovina

<sup>2</sup> Scientific Veterinary Institute “Novi Sad”, Rumenački put 20, Novi Sad 21000, Serbia

<sup>3</sup> The Department of Microbiology, Faculty of Veterinary Medicine, University of Belgrade, Bulevar oslobođenja 18, Belgrade 11000, Serbia

Received: 30 January 2023 • Accepted: 27 June 2023

Published online: 7 September 2023

## ABSTRACT

*Nocardia cyriacigeorgica* is a well-known agent of human nocardiosis and is considered an emerging pathogen, however, its identification to the species level is complex for many clinical laboratories. Available data on the clinical significance of *N. cyriacigeorgica* in veterinary medicine are sparse and mainly concern isolated reports of pyogranulomatous lesions in domestic animals. We report a case of severe bovine mastitis caused by *N. cyriacigeorgica* that did not respond to conventional antimicrobial therapy in a small holding in Bosnia and Herzegovina. After isolation of the pathogen, further identification by routine microbiological methods was not possible. Susceptibility to antimicrobials was tested using the disc diffusion method according to published recommendations. The sample was also tested by MALDI-ToF MS with inconclusive results. In addition, 16S rRNA sequence analysis, verified by multilocus sequence analysis (MLSA) using the *gyrB*, 16S rRNA, *secA1*, and *hsp65* sequences, confirmed the species *N. cyriacigeorgica*. To our knowledge, this is the first report of isolation of *N. cyriacigeorgica* from a clinical case of bovine mastitis in a European dairy farm and the first MLSA method approach to distinguish a *Nocardia* spp. strain isolated from animals.

